# Cases in Gastroenterology and Liver disease

4.3.20

Dr Jennifer Fisher
Gastroenterology SpR

# Introduction

- We will not cover everything
- Ask Questions
- Interact with the cases

SIMPLY GASTRO

# Luminal Topics

- GORD
- Peptic ulcer disease
- IBD
  - UC
  - IBD
- Carcinoma

SIMPLY
GASTRO

# Case 1

- 35 Y.O gentleman presents with epigastric and central abdominal pain.
- Previous episode few years before – took OTC indigestion meds
- Lasts 30-60 mins
- Worse late at night and can wake him from sleep
- Smokes 10-15/day
- Drinks 30 units per week

- Has been feeling generally tired and lethargic

SIMPLY GASTRO

# Examination

- HR 100, BP 100/50, RR 24, SATs 98% air, T36.5
- Epigastric tenderness
- PR - melaena

SIMPLY GASTRO

# Investigations

- Bloods
  - FBC
  - LFTs
  - Haematinics

  - Hb 102
  - MCV 71
  - WCC 8.9
  - Plts 350
  - Iron 4 (14-31)

TIBC 76 (45-70)

Ferritin 6 (20-30)

SIMPLY GASTRO

# Dyspepsia and GORD

- Pain/discomfort in the upper abdomen
  - Ulcer like – epigastric pain
  - Reflux – heartburn and regurgitation
  - Dysmotility – bloating & nausea

- Most causes are recurrent and intermittent

- Only curative treatments are H.Pylori eradication and surgery

SIMPLY GASTRO

# Alarm symptoms

- Any sign of GI bleeding
- Progressive unintentional weight loss
- Dysphagia
- Persistent vomiting
- Iron deficiency anaemia
- Epigastric mass

- Investigate with an endoscopy

- Medication review
- Lifestyle advice
- Consider cardiac, biliary and pancreatic causes

SIMPLY GASTRO

# Upper Endoscopy

Gastric ulcer

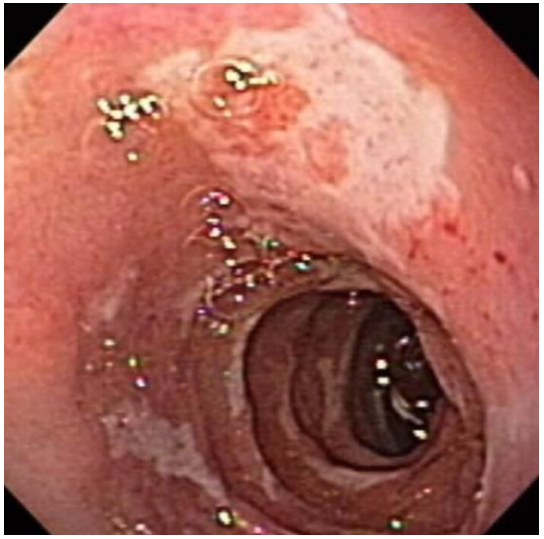

Duodenal ulcer

SIMPLY GASTRO

# Causes of upper GI bleeding

- Peptic ulcer disease — 45-55%
- Oesophagogastric varices — 15-20%
- Arteriovenous malformations — 5-10%
- Mallory-Weiss tears — 5-10%
- Tumors — 5-10%
- Dieulafoy's lesion — 1-3%
- Other — 10-15%

SIMPLY GASTRO

# H.Pylori

- Increased risk of gastric Ca (3-6x)
- Majority of PUs

- Non invasive tests
  - C-urea breath test
  - Stool antigen
    - Diagnosis of infection and monitoring after infection has cleared
    - False negative after PPI use
  - Serology
    - Diagnosis of infection
    - Antibodies remain +ive after infection has cleared

SIMPLY GASTRO

- Invasive tests
  - CLO test
    - Diagnosis in patient undergoing endoscopy
    - Highly sensitive and specific
    - False negative after recent PPI use
  - Histology
    - Direct visualisation of organism

- Eradication

| ANTIBIOTIC* | PROTON PUMP INHIBITOR |
|---|---|
| Amoxicillin 1g twice daily<br>**and either:**<br>Clarithromycin 500mg twice daily<br>**or**<br>Metronidazole 400mg twice daily**<br>(whichever was not used first-line) | Esomeprazole 20mg twice daily<br>or<br>Lansoprazole 30mg twice daily<br>or<br>Omeprazole 20–40mg twice daily<br>or<br>Pantoprazole 40mg twice daily<br>or<br>Rabeprazole 20mg twice daily |
| **Previous clarithromycin and metronidazole exposure** | |
| Amoxicillin twice daily<br>**and either:**<br>A quinolone twice daily<br>**or**<br>Tetracycline twice daily<br>(whichever has the lowest acquisition cost) | |

SIMPLY GASTRO

# Barretts Oesophagus

- Columnar epithelium lining the lower oesophagus
- Adaptive change to reflux oesophagitis
  - May become metaplastic or pre-malignant
- 30 fold increased risk of adenocarcinoma
- Surveillance every 3-5 years
  - 4 quadrant biopsies every 2cm
  - Ascetic acid spray

SIMPLY GASTRO

# Ascetic acid spray

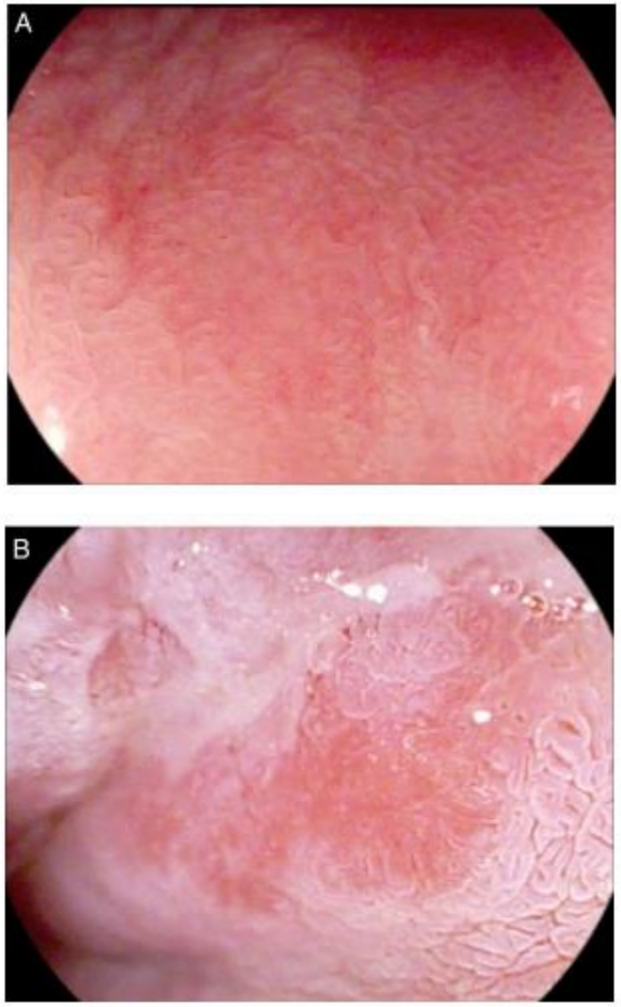


SIMPLY GASTRO

# Case 1b – slightly different scenario

- 35 Y.O gentleman presents with epigastric and central abdominal pain.
- Previous episode few years before – took OTC indigestion meds
- Lasts 30-60 mins
- Worse late at night and can wake him from sleep
- Smokes 10-15/day
- Drinks 30 units per week

SIMPLY GASTRO

- Presents with haematemesis and melaena

- Examination
  - HR 120
  - BP 90/60
  - Pale and sweaty
  - RR24, Sats 99% air, apyrexial

SIMPLY
GASTRO

# Things to consider

- Alcohol intake
  - Signs of Chronic liver disease
- NSAIDS
- PMHx
    - PUs
    - Liver disease
  - Clotting disorders/anticoagulants

SIMPLY
GASTRO

# What to look for on your examination?

- BP and HR
- Anxiety/confusion
- RR
- Urine output
- Signs of liver disease
- PR – melaena/fresh red blood

ANY SIGNS OF SHOCK?

SIMPLY GASTRO

# Investigations

- CXR
- ABG – oxygenation, glucose, lactate, Hb, electrolytes
- Bloods inc FBC, U&Es, LFTs, Clotting, G&S/X-match
- Urine output – catheterise
- ECG

SIMPLY GASTRO

# Management

- ABC
- IV access
- IVI + NBM
- Transfuse (if necessary) – Packed red cells, FFP, platelets
  - (Major haemorrhage protocol if needed)
- PPI
- Early endoscopy once stable
- +/- Terlipression + broad spec abx if considering variceal bleed

SIMPLY GASTRO

# Endoscopic treatment

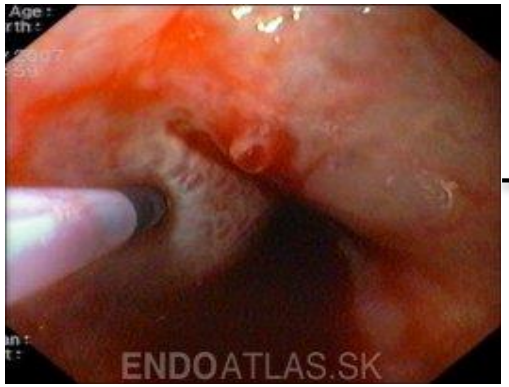


Adrenaline injection

Banding of oesophageal varices

Endoclips

**Ulcer bleeds**

Glue for gastric varices

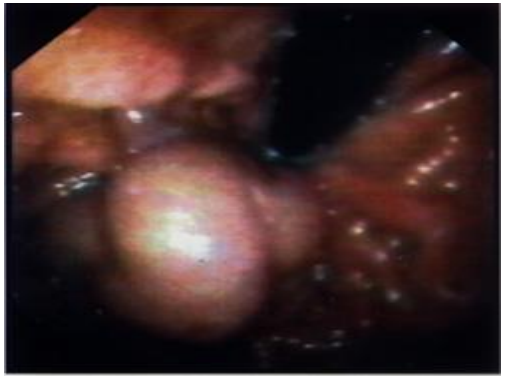

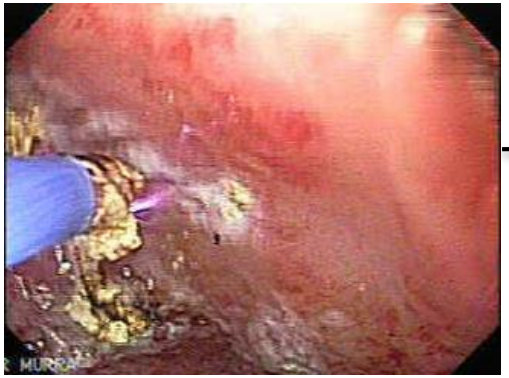

Argon plasma coagulation

SIMPLY GASTRO

# Case 2

- 30 year old female presents to A&E with 3 month history of abdominal pain & bloody diarrhoea
- 6kg weight loss
- No PMHx
- Ex-smoker (quit 6 months ago)
- Occasional alcohol
- No significant FHx

SIMPLY GASTRO

# Examination

- Looks pale
- Thin
- HR 110, BP 100/60, RR 16, Sats 99% Air, T 38.2
- Abdomen SNT, BS +
- PR – fresh red blood

- Most likely diagnosis

SIMPLY GASTRO

# Causes of diarrhoea

- **Infective**
  - Bacterial
  - Viral
  - Protozoal

- **Inflammatory Bowel Disease**
  - Crohn's
  - Ulcerative Colitis

- Malignancy

- Drugs
- Hyperthyroidism
- Ischaemic
- Radiation Colitis
- Malabsorptive States
- Bacterial Overgrowth
- Neuroendocrine tumours

- Irritable Bowel Syndrome
- Diverticular Disease
- Constipation (with overflow)
- Alcohol excess
- Fictitious

SIMPLY GASTRO

# What questions to ask

- How long? <2/52 vs ≤ 4/52 vs >4/52
- Systemic symptoms
  - Pyrexial, dehydration, severe pain, immunocompromised, elderly,
- How frequent? Does it occur at night?
- What is the consistency? 1 (rock hard pellets) → 4 (soft sausage) → 7 (like water)
- If there is blood is it on stool vs in pan vs on paper?
- PMH? Drug Hx? (don't forget recent abx) FH? Ethnicity?
- Foreign travel? Anyone else ill? Trauma?
- N+V? ↓appetite? Loss of weight? Night sweats?
- Any eye vs skin vs joint vs liver problems?

SIMPLY GASTRO

# Investigations

- Bloods – FBC, U&Es, LFTs, VBG, CRP/ESR
- AXR
- Stool
  - MC&S
  - C.diff
  - Faecal Calprotectin

- Truelove and Witts score

SIMPLY GASTRO

# Truelove and Witts score

| Parameter | Mild | Moderate | Severe |
|---|---|---|---|
| Bloody stool/day | <4 | ≥4 or more if | ≥6 and |
| Pulse | <90 bpm | ≤90 bpm | > 90 bpm or |
| Temperature | <37.5 C | ≤ 37.8 C | > 37.8 C or |
| Haemoglobin | >11.5 g/dL | >10.5 g/dL | <10.5 g/dL |
| ESR or | <20 mm/h | ≤ 30 mm/h | >30 mm/h or |
| CRP | normal | ≤ 30 mg/l | >30 mg/l |

SIMPLY GASTRO

# Acute severe colitis

- LMWH – even if rectal bleeding!!!!
- IVI
- Monitor and replace electrolytes
- IV steroids + Vit D
- Topical mesalazine
- Abx only if toxic megacolon/C.diff infection likely

+/- Surgical review

+/- unprepped flexi sig + biopsies for CMV

SIMPLY GASTRO

# Review at 3-5 days

- Travis Criteria
- 24 hour stool frequency >8
- OR 3-8/day + CRP >45%
- Colectomy risk 85% without 2nd line treatment

- INFLIXIMAB
- (ciclosporin)

SIMPLY GASTRO

SIMPLY
GASTRO

- Ecco Eguide
  - http://www.e-guide.ecco-ibd.eu/
- Close working relationship gastro and surgeons
- IV steroids 1st line
- If using second line – need extended viral screen + vaccinations

SIMPLY GASTRO

# Case 3

Which ONE of the following is not a recognised extraintestinal manifestation of inflammatory bowel disease?

a) Episcleritis
b) Primary sclerosing cholangitis
c) Pyoderma gangrenosum
d) Rheumatoid arthritis
e) Vitamin B12 deficiency

SIMPLY GASTRO

# Case 3

Which ONE of the following is not a recognised extraintestinal manifestation of inflammatory bowel disease?

a) Episcleritis
b) Primary sclerosing cholangitis
c) Pyoderma gangrenosum
d) Rheumatoid arthritis
e) Vitamin B12 deficiency

SIMPLY GASTRO

# Extra intestinal manifestations

Ankylosing spondylitis



Erythema nodosum

Pyoderma gangrenosum

Episcleritis

SIMPLY GASTRO

# Case 4

Which ONE of the following is more characteristic of ulcerative colitis rather than Crohn's disease?

a) Cobblestone lesions
b) Crypt abscesses
c) Granulomas
d) Fistula formation
e) Transmural inflammation

SIMPLY GASTRO

Which ONE of the following is more characteristic of ulcerative colitis rather than Crohn's disease?

a) Cobblestone lesions
b) Crypt abscesses
c) Granulomas
d) Fistula formation
e) Transmural inflammation

SIMPLY GASTRO

## Comparisons of various factors in Crohn's disease and ulcerative colitis

| | Crohn's Disease | Ulcerative Colitis |
|---|---|---|
| Involves terminal ileum | Commonly | Seldom |
| Involves colon? | Usually | Always |
| Involves rectum? | Sometimes Seldom | Usually |
| Bile duct involvement? | Not associated | Higher rate of Primary sclerosing cholangitis |
| Distribution of Disease | Patchy areas of inflammation | Continuous area of inflammation |
| Endoscopy | Linear and serpiginous (snake-like) ulcers | Continuous ulcer |
| Depth of inflammation | May be transmural, deep into tissues | Shallow, mucosal |

SIMPLY GASTRO

# UC versus CD

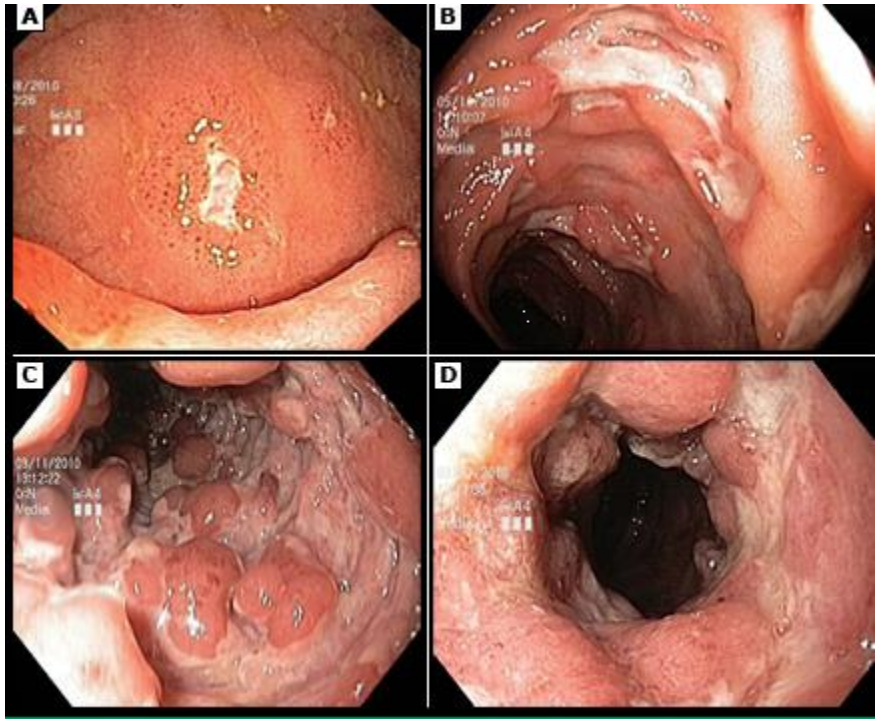


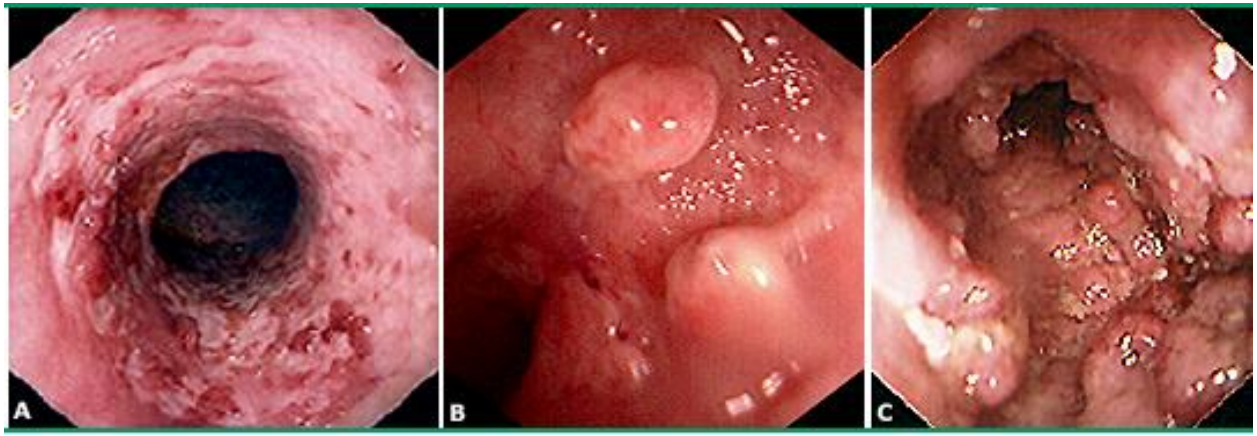


SIMPLY GASTRO

# Complications of IBD

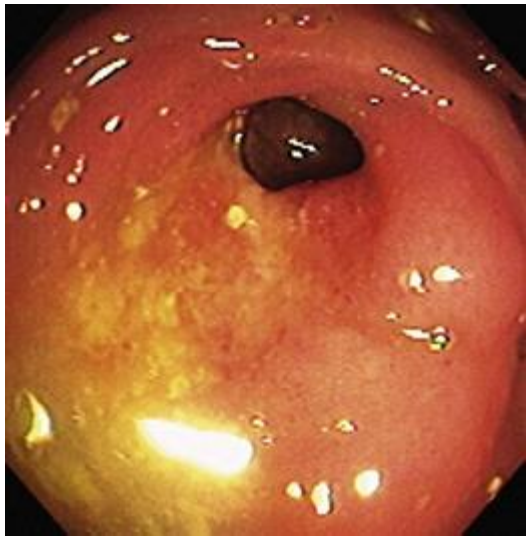

Stricture

Fistula

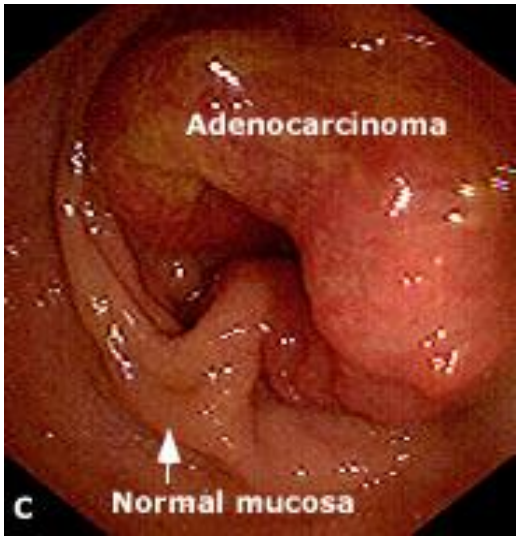


Bowel cancer

SIMPLY GASTRO

# Case 5

Which ONE of the following is more suggestive of colorectal cancer?

a) Change in bowel habit towards diarrhoea in 45-year old woman

b) Hb 100 g/L (130-180 g/L) MCV 100 (80-96 dL) in 60-year old man

c) Painful PR bleeding in 55-year old man

d) Palpable pelvic mass in 59-year old woman

e) Previous medical history of diverticular disease in 63-year old man

SIMPLY GASTRO

# “Red Flag” bowel symptoms

- Rectal bleeding with an associated change in bowel habit to looser stools or persistent increased bowel frequency for over six weeks
- Rectal bleeding without anal symptoms in an individual aged over 60
- Persistent change in bowel habit for over six weeks with increased bowel frequency or looser stools in an individual aged over 60
- Iron deficiency anaemia without an obvious cause (Hb <11 g/dl in men or <10 g/dl in postmenopausal women).
- Palpable right sided abdominal mass
- Palpable rectal (not pelvic) mass

SIMPLY GASTRO

# Case 5

Which ONE of the following is more suggestive of colorectal cancer?

a) Change in bowel habit towards diarrhoea in 45-year old woman

b) Hb 100 g/L (130-180 g/L) MCV 100 (80-96 dL) in 60-year old man

c) Painful PR bleeding in 55-year old man

d) Palpable pelvic mass in 59-year old woman

e) Previous medical history of diverticular disease in 63-year old man

SIMPLY GASTRO

# Case 6

Which ONE of the following is **NOT** associated with an increased risk of colorectal cancer?

a) Aspirin
b) Colorectal polyps
c) Obesity
d) Smoking
e) Ureterosigmoidostomy

SIMPLY GASTRO

# Case 6

Which ONE of the following is **NOT** associated with an increased risk of colorectal cancer?

a) Aspirin
b) Colorectal polyps
c) Obesity
d) Smoking
e) Ureterosigmoidostomy

SIMPLY GASTRO

# Risk Factors and Distribution (%) of Colorectal Ca.

**Increased risk**
- Increasing age
- Animal fat (saturated) and red meat consumption
- Sugar consumption
- Colorectal polyps
- Family history of colon cancer or colonic polyps
- Chronic inflammatory bowel disease
- Obesity (body and abdominal)
- Smoking
- Acromegaly
- Abdominal radiotherapy
- Ureterosigmoidostomy

**Decreased risk**
- Vegetable, garlic, milk, calcium consumption
- Exercise (colon only)
- Aspirin (including low dose) and other NSAIDs

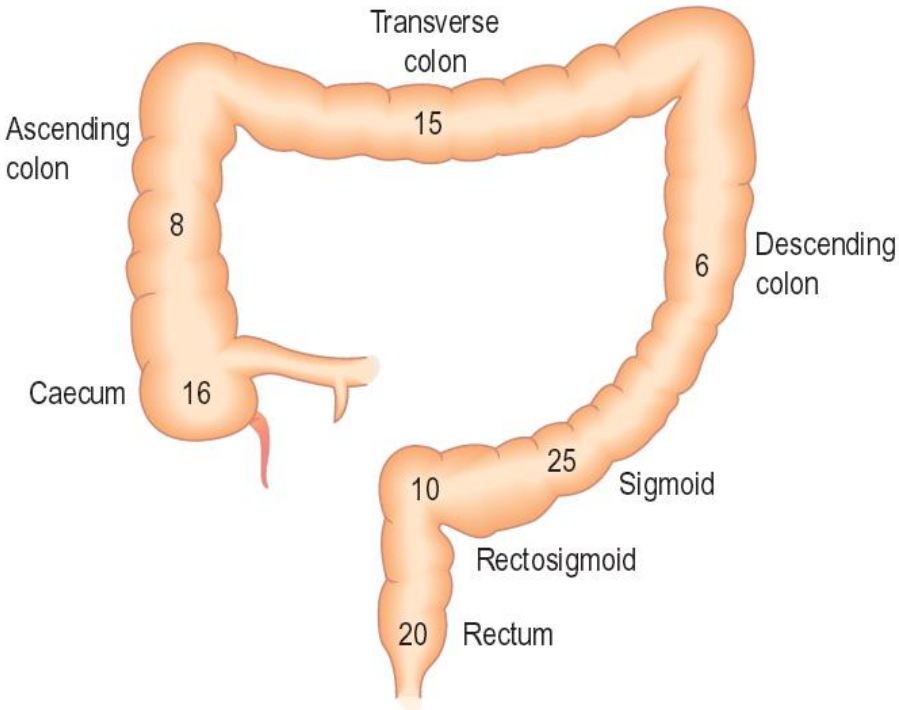


SIMPLY GASTRO

# Investigations for bowel cancer

- **Colonoscopy (or CT pneumocolon/colonography)**

- **Blood tests:** FBC, LFTs, CEA

- **If bowel cancer found then also do:**

❑ CT scan of the chest, abdomen and pelvis to stage disease and look for local spread and metastatic disease.

❑ MRI +/- endoanal ultrasound but **ONLY** with rectal cancer.

- Faecal occult blood (FOB) stool test is only used for screening asymptomatic patients and **NOT** for diagnosing bowel cancer

SIMPLY GASTRO

# Causes of Dysphagia

| Disorders of the mouth and tongue | Extrinsic pressure |
|---|---|
| E.g. tonsillitis | Mediastinal glands |
| **Neuromuscular disorders** | Goitre |
| Pharyngeal disorders | Enlarged left atrium |
| Bulbar palsy | |
| Myasthenia gravis | **Intrinsic lesion** |
| | Benign stricture |
| **Oesophageal motility disorders** | Malignant stricture |
| Primary oesophageal disease<br>Achalasia<br>Other oesophageal dysmotility<br>Eosinophilic oesophagitis* | Oesophageal web or ring<br>Foreign body<br>Pharyngeal pouch |
| Systemic disease<br>Diabetes mellitus<br>Chagas' disease<br>Scleroderma | |

SIMPLY GASTRO

# What questions to ask

- How long have symptoms have been going on?
- Progressive vs sudden
- Dysphagia for solids +/- liquids
- Is there N+V? Haematemesis? Odynophagia?
- Is there anorexia? Loss of weight?
- Is there PMH of reflux? Regurgitation? Night cough?
- PMH? DH? Smoker? Alcohol? Immunosuppressed?

SIMPLY GASTRO

# Case 7

A 67-year woman was referred by the GP with progressive dysphagia for solids for 3 months. She has lost 5kg in weight. O/E No abnormal findings.

What is the NEXT most appropriate investigation?

a) Barium swallow

b) CT chest and abdomen

c) FBC, INR, U&E and LFT

d) pH and upper GI manometry studies

e) Upper GI endoscopy

SIMPLY GASTRO

# Investigations

OGD

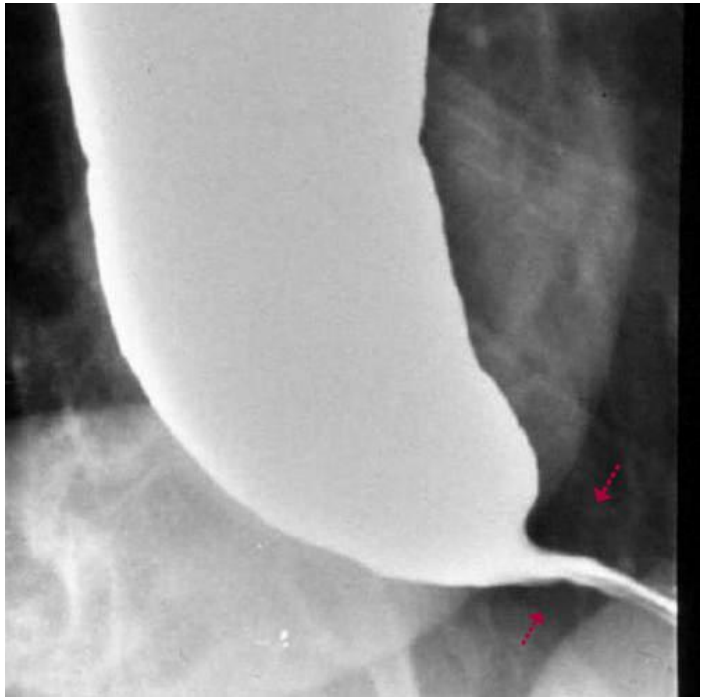

Barium swallow

SIMPLY GASTRO

# Case 8

Which ONE of the following is **NOT** an indication for insertion of Nasogastric tube?

A) Administration of medication in a patient with a reduced GCS

B) Feeding a patient with gastric outflow obstruction

C) Provision of nutrition and hydration in a ventilated patient

D) Provision of specific nutrition therapy in children with small bowel Crohn's disease

E) Relief of symptoms in patient with small bowel obstruction

SIMPLY GASTRO

# Case 8

Which ONE of the following is **NOT** an indication for insertion of Nasogastric tube?

A) Administration of medication in a patient with a reduced GCS

B) Feeding a patient with gastric outflow obstruction

C) Provision of nutrition and hydration in a ventilated patient

D) Provision of specific nutrition therapy in children with small bowel Crohn's disease

E) Relief of symptoms in patient with small bowel obstruction

SIMPLY GASTRO

# Enteral vs Parenteral Nutrition

- Simpler, more physiological, cheaper and less complicated.
- Given via tube
- Problems with using mouth but gut is working:

A. Impaired swallowing
B. Reduced GCS
C. Ventilated
D. Oesophageal or gastric obstruction
E. Severe pancreatitis
F. Supplement oral feeding in certain conditions

- Nutrients delivered directly into the blood bypassing the gut
- Requires intensive monitoring and associated with complications to do with placement, infection and electrolyte imbalance
- Use when gut is not working:

A. Blockage of the gut (mechanical obstruction)
B. Gut failing to work (ileus)
C. Gut perforations where feeding will result in worsening infections
D. Where a large part of the gut has been removed and the patient cannot absorb enough food (short bowel syndrome)

SIMPLY GASTRO

# Liver disease topics

- LFTs
- Chronic liver disease
- Alcoholic hepatitis
- Acute liver failure
- Malignancy
- Viral Hepatitis

SIMPLY
GASTRO

# What bloods do we look at?

- ALT/AST
- Gamma GT
- ALP
- Bilirubin
- Albumin
- INR/PT

SIMPLY GASTRO

- ALT - hepatocellular damage
- ALP – cholestasis
- (If ALP raised check gamma GT)
- Causes of isolated ALP rise
  - Bone mets/primary bone cancer
  - Vit D def
  - Recent fractures
  - Renal osteodystrophy

SIMPLY GASTRO

- What if bili is raised but ALT and ALP are normal?

- Gilberts
- Haemolysis
  - Blood film
  - FBC
  - Retics
  - Haptoglobin
  - LDH

SIMPLY GASTRO

# Assessing hepatic function

- Main synthetic functions
  - Conjugation and elimination of bilirubin
    - Serum bilirubin
  - Synthesis of albumin
    - Serum albumin
  - Synthesis of clotting factors
    - INR/PT
  - Gluconeogenesis
    - Serum glucose

SIMPLY GASTRO

# Case 9

- 25 year old presents with yellow discoloration of sclera and oral mucosa.
- Bloods show elevated unconjugated bilirubinaemia
- What is the most likely diagnosis
  - Stone in CBD
  - Pancreatic head Ca
  - Pancreatic pseudocyst
  - Sickle Cell
  - HCC

SIMPLY GASTRO

# Bilirubin

- Breakdown product of RBCs (Haem)
- Unconjugated bili – not water soluble
- Conjugated in the liver – water soluble
  - Most excreted in bile
  - Some stays in large intestine – urobilinogen – sterobilinogen
- Increased Bili is either
  1. Increased production – e.g haemolysis
  2. Decreased excretion – blocked bile ducts
     - Cirrhosis
     - Hepatits etc

SIMPLY GASTRO

# Bilirubin Transport

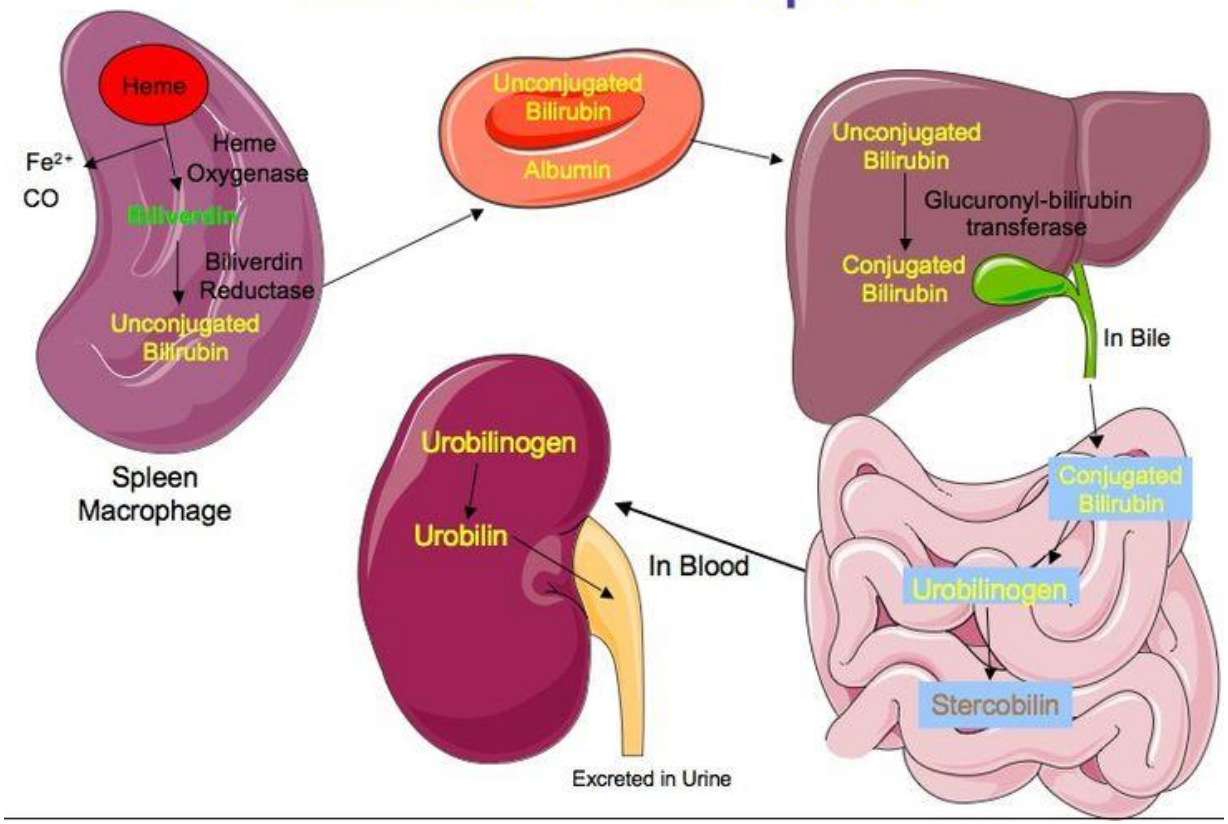


SIMPLY GASTRO

# Back to the case

- 25 year old with jaundice and raised unconjugated bili
  1. Either increased RBC breakdown
  2. Issue with conjugating ability of the liver

A. Stone in CBD
   - Stone would block excretion of bili into bile
   - Conjugated bilirubinaemia

B. Pancreatic head Ca
   - Biliary obstruction similar to A

C. Pancreatic pseudocyst
   - Biliary obstruction – conjugated

D. Sickle Cell
   - If haemolysis was severe enough – unconjugated bilirubinaemia
   - If low level liver could keep up – conjugated

E. HCC
   - Biliary obstruction again – conjugated

- If no history of SCD what else could be the cause?

SIMPLY GASTRO

# Causes of jaundice

| Prehaptic | Hepatic | Extrahepatic |
|---|---|---|
| Haemolysis | Viral hepatitis | Gallstones |
| | Cirrhosis | Intra & extrahepatic cancer |
| | Alcoholic liver disease | PSC |
| | NAFLD | Biliary strictures |
| | Drugs (inc TPN) | Pancreatitis |
| | PBC | |
| | Pregnancy | |
| | Infiltrations | |
| | Congenital conditions | |
| | Heart failure | |
| | Sepsis & hypoperfusion | |
| | Intrahepatic cholestasis | |

MPLY
GASTRO

# So where do we start?

- Do not interpret LFTs on their own
  - History
  - Examination
  - Bloods
  - Imaging
- Is it liver disease?
- What type of liver disease?
- How severe is it?
  - Stage
  - Fibrosis/cirrhosis

SIMPLY GASTRO

# History

- How long and was it sudden or progressive?
- Any new medications/OTC remedies/illicit drugs/etoh?
- Any risk factors for viral hepatitis: a) foreign travel b) sex c) injections/tattoos d) operations/transfusions e) FH
- Has it happened before? PMH?
- Feel unwell? Anorexia? Loss of weight? Abdo pain? Fevers?
- Sx of liver disease: a) pruritis b) bleeding c) bruising d) abdo distension e) confusion
- Pregnant?

SIMPLY GASTRO

| Causes of Hepatomegaly | | Causes of Splenomegaly | |
|---|---|---|---|
| **Infective** | Viral Hepatitis<br>EBV<br>Malaria<br>Leishmaniasis | **Infective** | EBV<br>Malaria<br>Leishmaniasis |
| **Malignant** | Hepatocellular Ca.<br>Leukaemia<br>Lymphoma<br>Secondary Ca. | **Malignant** | Leukaemia<br>Lymphoma |
| **Metabolic/ Infiltration/ Inflammatory** | Fatty<br>Amyloid<br>Haemochromatosis<br>Storage Diseases<br>Sarcoid | **Metabolic/ Infiltration/ Inflammatory** | Amyloid<br>Sarcoid<br>Storage Diseases<br>Haemolytic Anaemia<br>Haemoglobinopathies<br>SLE |
| **Cardiovascular** | Right Heart Failure<br>Budd-Chiari | **Cardiovascular** | Portal Hypertension |
| **Other** | Reidel's Lobe<br>Low Diaphragm | | |

# Case 10

- 45 Y.O male presents with 6 months of reduced appetite and weight loss.
- 1 month history of ankle swelling
- Complaining of morning nausea and vomiting
- Despite weight loss his trousers feel tighter

- What else would you like to ask him?

SIMPLY GASTRO

# Examination

- Pitting oedema to ankles
- Muscle wasting from limbs
- 9 spider naevi on upper trunk
- Abdomen is distended

- Any thing else you want to know?

SIMPLY GASTRO

# Investigations

- Bloods
  - Hb 126, MCV107, plts 127
  - Na 131, K 4.2, creat 101
  - ALT 276, ALP 351, Bili 25
  - INR 1.4, albumin 28

- US
  - Hypoechoic liver with an irregular surface. Moderate volume ascites.

  - What else would you look at on the US?
  - Portal vein flow
  - Spleen size

SIMPLY GASTRO

# Diagnosis

- Chronic liver disease
  - Need to establish the cause
    - Alcohol
    - NASH
    - Hepatitis
  - Low albumin and INR
  - Low platelets – portal hypertension
  - Alcohol withdrawal/ abstinence

SIMPLY GASTRO

# Chronic Liver disease screen

- Bloods
  - Viral
    - Hep B, C, HepBsAg, HepB surface Abs, Hep B core abs, Anti HCV
    - HIV
  - Autoantibodies
    - ANA, AMA, anti-LKM, anti-SMA
  - Immunoglobulins
  - Ferritin & TSATS
  - Coeliac screen
  - Alpha 1 antitrypsin
  - Lipids
  - AFP
  - Caeruloplasmin and copper (only if <40)

- US abdomen inc portal and hepatic vein dopplers

SIMPLY GASTRO

# Case 11

- Same man – 45 alcohol related cirrhosis
  - Unfortunately hasn't stopped drinking
  - Presented with nausea and vomiting, unable to keep anything down
  - Daughter came to see him today and thinks he's more confused than normal

  - What else do you want to know?

SIMPLY GASTRO

- Was drinking 3 bottles of wine per day until 3 days ago when he got D&V now unable to keep anything down
- Worsening abdominal distention, now feeling short of breath
- Complaining of RUQ pain
- No temps/cough/cold/dysuria
- Jaundiced

SIMPLY GASTRO

# Examination

- Visibly Jaundiced
- Large volume ascites, pitting oedema to sacrum
- JVP +3cm
- Tender RUQ, no guarding/rebound
- Spider naevi as before
- Dry mucus membranes
- Asterixis, GCS 14/15

SIMPLY GASTRO

- Observations
  - HR110, BP 90/60, Temp 37.4, Sats 96% air, RR 22 BM 4.5
- Bloods
  - Hb 110, MCV 109, Plts 98, WCC 9.7, CRP 70
  - Na 125, K 2.8, Creat 250, urea 10
  - Bili 150, ALT 50, ALP 98, Albumin 24, INR 2.0
- CXR
  - Small bilateral pleural effusions
  - No focal consolidation
- Urine dip
  - Bili ++
  - Otherwise unremarkable

SIMPLY GASTRO

# Decompensated CLD

- Decompensated Alcohol related liver disease
  - Possible causes
    - Infection
    - GI bleed
    - Alcoholic hepatitis
    - Portal vein thrombosis (acute)
    - HCC
    - Drugs
    - Constipation
    - Ischaemia
    - Dehydration

SIMPLY GASTRO

# BSG liver bundle

- Optimal care for decompensated cirrhotic in first 24 hours
- Basic principles
- R – renal
  - AKI
  - Hyponatreamia
- I – infection
  - Full septic screen inc. ascitic tap (regardless of INR/platelets)
- N – nutrition
  - Hugely catabolic
- G – GI
  - UGIB
  - Constipation
- Alcohol withdrawal
  - IV pabrinex
  - Chlordiazepoxide
- Gastro review as soon as possible

SIMPLY GASTRO

# Encephalopathy

- Can mimic alcohol withdrawal/agitation/↓GCS/fits
- **ALWAYS** need to exclude hypoglycaemia
- Rx possible causes:

  low Na/K

  sepsis

  blood transfusions

  constipation
- CT head if no improvement after 24 hours of Rx
- Stop potentially offending drugs:

  diuretics

  BDZs

SIMPLY GASTRO

# Alcoholic hepatitis

- History of recent heavy alcohol intake
- Serum bili >80
- ALT <300
- Exclusion of autoimmune, viral, malignancy

- Maddrey/GAHS
  - >32/>9
- Steroids 40mg OD
- Reassess response at 7/7
  - Lille score
  - Continue vs stop

SIMPLY GASTRO

# Case 12

- 30 y.o woman brought to A&E by husband after being found at home with multiple empty blister packs
- Thinks it happened approx. 7 hours before they arrived

- Paracetamol, Temazepam and ibruprofen
- Not on any prescribed medications, CBT only
- Depressed since birth of child 3 months ago
- No previous self harm attempts

SIMPLY GASTRO

# Examination

- Alert GCS 15
- All observations are within normal limits
- Mild abdominal tenderness RUQ

- Bloods
  - ALT 90
  - ALP 37
  - Bili 30
  - INR 1.4
  - Albumin 34
  - Creat 56

VBG

PH 7.29
Lactate 6.5
Glucose 5.6

Paracetamol level 260

SIMPLY GASTRO

# Management

- NAC
- IVI
- Repeat bloods 6 hours
- ITU review

SIMPLY
GASTRO

# Review at 36 hours

- GCS 15
- Bloods
  - ALT 5600, ALP 50, Bili 100, INR 3.5, Lact 2.0, creat 100, pH 7.33
  - What next?

  - What might you be concerned about
  - Has had 3 bags of NAC
    - Continue or stop?
    - Vit K?

SIMPLY GASTRO

# Review Day 3

- GCS 13/15
- ALT 10,000, ALP 150, bili 250 INR 6.0, Creat 250, pH 7.26, Lactate 5, glucose 3.5
- Asterixis

SIMPLY GASTRO

# Kings criteria

| | | |
|---|---|---|
| Arterial pH < 7.30 | No | **Yes** |
| INR > 6.5 (PT > 100 sec) | **No** | Yes |
| Creatinine 3.4 mg/dL (300 µmol/L) | **No** | Yes |
| Grade III or IV hepatic encephalopathy | No | **Yes** |
| Other predictors of poor prognosis without transplant | | |
| Lactate > 3.5 mmol/L after fluid resuscitation (<4 hrs) OR lactate > 3 mmol/L after full fluid resuscitation (12 hours) | No | **Yes** |
| Phosphate > 3.75 mg/dL (1.2 mmol/L) at 48-96 hours | **No** | Yes |

**2** criteria

Transfer to transplant center and list for transplant.

While not part of the King's Criteria, hyperlactatemia is a strong predictor of poor prognosis for survival without transplantation.

Copy Results | Next Steps

**Also from MDCalc...**

**Related Calcs**

- NAC Dosing (Tylenol OD)
- Hepatic Encephalopathy Grades
- Maddrey's Discriminant Function

**You might be interested in...**

**Partner Content**

Calculated Decisions: King's College Criteria
Emergency Medicine Practice

**Content Contributors**

- Vince Nguyen, MD

SIMPLY GASTRO

# Paracetamol Toxicity

- Paracetamol can cause Acute liver failure
- Stage 1 (<24 hours)
  - Anorexia, nausea, vomiting
  - Bloods may be normal
- Stage 2 (24-72 hours)
  - May appear to have improved clinically
  - May notice derranged ALT, INR, bili +/- nephrotoxicity
- Stage 3 (72-96 hours)
  - Hepatic stage
  - Severe signs of hepatotoxicity appear
  - Most death occur in this stage, multi-organ failure
- Stage 4 (4 days-2 weeks)
  - Recovery phase

SIMPLY GASTRO

# Case 13

- 55 year old woman presents with painless jaundice 5/7
- 5kg weight loss
- Smokes 10 per day, social drinker
- No foreign travel, nil PMx, no new medications
- On examaintion, visibly jaundiced, HR 100, BP 105/65, RR 16, Sats 98% air, Temp 38
- Abdomen tender RUQ, PR normal stool, no ascites

- What is the most appropriate next investigation?
  A. CT abdomen with contrast
  B. ERCP
  C. US abdomen
  D. MRCP
  E. Liver biopsy

SIMPLY GASTRO

# Case 12

- 55 year old woman presents with painless jaundice 5/7
- 5kg weight loss
- Smokes 10 per day, social drinker
- No foreign travel, nil PMx, no new medications
- On examaintion, visibly jaundiced, HR 100, BP 105/65, RR 16, Sats 98% air, Temp 38
- Abdomen tender RUQ, PR normal stool, no ascites

- What is the most appropriate next investigation?
  A. CT abdomen with contrast
  B. ERCP
  C. US abdomen
  D. MRCP
  E. Liver biopsy

SIMPLY GASTRO

# Investigations

Immediate:

- Blood tests: FBC, U+E, LFTs, INR, Blood cultures, glucose, amylase, paracetamol, salicylate
- Non-blood tests: CXR, MSU, ABG

Specialised/liver screen:

- HAV IgM, HBsAg, HCV IgG, HIV
- Autoimmune screen, Immunoglobulins, ANCA
- AFP
- Ferritin
- (~~Caeruloplasmin,~~ alpha-1-antitrypsin)
- Abdominal ultrasound

SIMPLY GASTRO

# Liver screen results

- **Autoimmune hepatitis**: ANA or Anti-smooth muscle pos + elevated IgG
- **PBC**: Anti-mitochondrial pos + elevated IgM
- **PSC**: ANCA pos + elevated IgG/M
- **Haemochromatosis**: ↑↑ Ferritin + Transferrin saturation ≥ 45% + HFE gene
- **Wilson's disease**: ↓ caeruloplasmin + ↑ 24 hr urinary Cu excretion + Kayser-Fleischer rings
- **Alpha-1-antitrypsin deficiency**: ↓ AAT + genotype
- **Hepatocellular carcinoma**: alphafeto protein (AFP)

SIMPLY GASTRO

# Immediate management

- ABC
- Intravenous broad spectrum antibiotics (if pyrexial)
- Rehydrate (iv/po) and monitor urine output (30ml/hr)
- Correct any electrolyte imbalance (Na/K)
- Urgent abdo ultrasound (US) for:1) ?Biliary dilatation 2) ?Focal liver lesion 3) ?PV thrombosis 4) ?Ascites
- If cholestatic LFTs + bile duct dilatation → ERCP
- If cholestatic LFTs + °bile duct dilatation → CT abdo
- If hepatitic LFTs + normal US → await liver screen +/- liver biopsy

SIMPLY GASTRO

# Case 14

A 37-yr-old man had some blood tests done by his GP and was referred with the following blood results:

HAV IgM-, HAV IgG+, HBsAg-, HBcAb+, HCV IgG+

Which ONE of the following is the correct diagnosis?

a) Acute HAV infection

b) Chronic HAV

c) Chronic HBV carrier

d) Chronic HCV carrier

e) Previous HBV infection but no longer infected

SIMPLY GASTRO

# Viral Hepatitis I

**Hepatitis A (HAV)**

- Only test for HAV IgM in jaundiced patients to see if acute HAV infection

**Hepatitis C (HCV)**

- Test for HCV IgG
- If negative then patient doesn't have HCV
- If positive then patient has had HCV in past or still has it then need to check HCV RNA: if 0 IU/mL then patient no longer has HCV but will **ALWAYS** be HCV IgG+

SIMPLY GASTRO

# Viral Hepatitis II

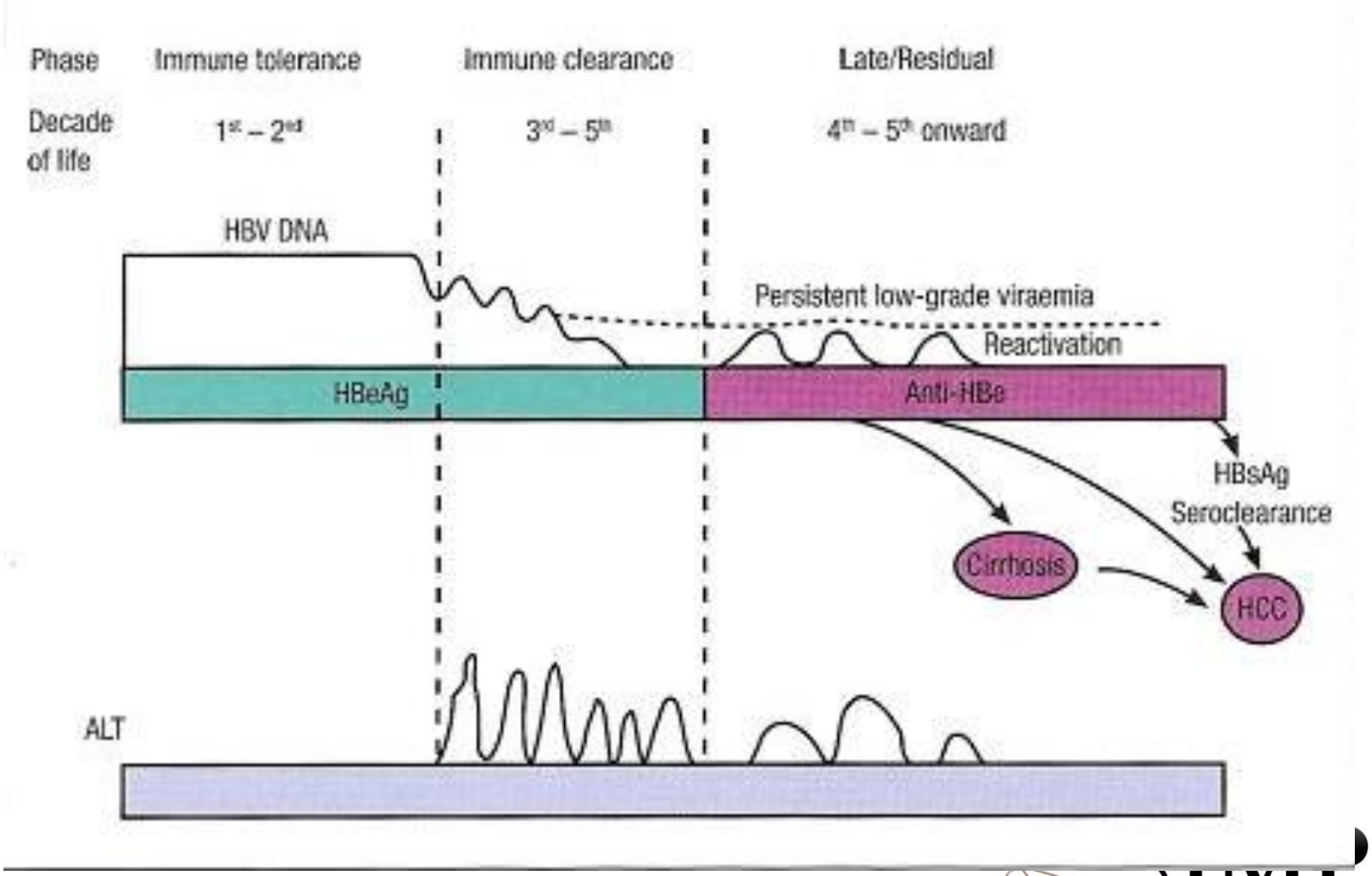


IMPLY GASTRO

# Viral Hepatitis III

**Hepatitis B (HBV)**

- If suspect HBV infection then test for HBsAg – if +ve then patient has HBV infection
- Only if positive then need to check HBV DNA (aka viral load) to quantify amount of HBV in patient
- HBcAb + will identify if patient has had HBV in the past – if you have been vaccinated then you will be HBcAb-
- HBeAg gives an indication of infectivity but nothing else
- HBsAb **ONLY** gives an indication of immunity
- If patient is HBV+ then possibility of also having HIV, HCV and delta virus

SIMPLY GASTRO

# So..

- HAV IgM-, HAV IgG+,
  - Previous Hep A infection, no acute infection

- HBsAg-
  - No Hep B infection
- HBcAb+
  - Previous Hep B infection

- HCV IgG+
  - Previous/current Hep C infection need to check
    - HCV RNA

SIMPLY GASTRO

# SO..

A 37-yr-old man had some blood tests done by his GP and was referred with the following blood results:

HAV IgM-, HAV IgG+, HBsAg-, HBcAb+, HCV IgG+

Which ONE of the following is the correct diagnosis?

~~a) Acute HAV infection~~

~~b) Chronic HAV~~

~~c) Chronic HBV carrier~~

d) ~~Chronic HCV carrier~~

e) Previous HBV infection but no longer infected

SIMPLY GASTRO

# Questions?

SIMPLY
GASTRO